

## Augmentation Rhinoplasty with Silicone Implants

Alamzeb Khan<sup>1</sup>, Obaidullah<sup>2</sup>, Amir Amanullah<sup>1</sup>

### ABSTRACT

**Background :** Nasal augmentation can be performed with autologous tissue or synthetic materials. There are many types of alloplastic materials. Silicone is our preferred material because of its easy availability, no issue of wrapping and softer consistency.

**Objective:** To evaluate the usefulness of silicone implant in augmentation rhinoplasty.

**Material & Methods:** All adult patients with either gender who were admitted in our unit and underwent nasal augmentation with Silicone implant were prospectively included in the study. The study was conducted in Aman Hospital Dabgari Garden Peshawar and Northwest General Hospital and Research center from January 2010 to December 2015.

**Results:** A total of 95 patients were included in the study out of these 56 (58.94%) were female and 39(41.05%) were male. The age ranged between 17 to 42 years. Only 2 (2.1%) patients had ended up with extrusion of the implants. One of the patients with extrusion was managed by dermal graft and in the second patient the implant was inserted again after a period of 6 months. The patients were satisfied with the surgery.

**Conclusion:** Rhinoplasty is one of the most frequently performed aesthetic procedures. Nose is augmented with either autologous tissue or synthetic implants. We have a good experience with the silicone. Silicone implants give good results because of its nasal cartilage like consistency. Patients with silicone augmentation were satisfied with the feel.

**Key words:** Augmentation rhinoplasty, Silicone implants.

This article may be cited as: Khan A, Obaidullah, Amanullah A.  
Augmentation Rhinoplasty with Silicone Implants. JSMC 2019;9(1):55-7.

### INTRODUCTION

Rhinoplasty is one of the most frequently performed aesthetic surgeries<sup>1</sup>. Nasal augmentation can be accomplished with either autologous tissue or with various alloplastic materials. The common autologous tissue includes cartilage, bone, dermal and dermofat grafts or combination of these. The cartilage and bone can give good results but they have their disadvantages like donor site morbidity, warping, resorption, increased operative time, unnatural hard feel<sup>2</sup>. The implants used for augmentation are mostly made of silicone and medpore. Silicone implants are the most commonly used<sup>3</sup>. We use silicone implants. Silicone implants are available in different shapes and sizes. These implants can be easily carved according to the need. Silicone implants are readily available and are softer than chondral cartilage. Silicone is chemically inert and can be sterilized easily. Solid silicone is non porous and does not harbor microorganisms

easily<sup>4</sup>. The complications of silicone implants are extrusion, infection and displacement<sup>5</sup>.

### MATERIAL AND METHODS

All adult patients with either gender who were admitted in Aman Hospital Dabgari garden and Northwest General Hospital Peshawar, and underwent nasal augmentation with Silicone implant were prospectively included in the study. The patients with diabetes and of age less than 17 years and more than 42 years were excluded from the study. Total duration of study is 6 years from January 2010 to December 2015. We examined the patients in detail preoperatively to determine the extent of the deformity and the skin type. We use Silastic implant of the minimum size that can serve the purpose. General anaesthesia administered in all cases in addition to local anaesthesia infiltration using 2% lidocaine with 1:100,000 epinephrine. Open rhinoplasty technique was used in all cases. We place the implant over the perichondrium of the nasal cartilages but under the periosteum of the nasal bone. The pocket for implant placement is kept minimum to prevent displacement of the implant. Implants are carved with Bard Parker blade size 15. We also make radiating incisions in the cephalic part of the implant on its posterior surface to prevent nasion level changes (Fig. 1). The incisions are closed with 6-0 Prolene and 6-0 Vicryl Rapide. Nasal splints are kept for one week. The skin stitches are removed after 5 days.

- 
1. Surgical Department, SGTH, Swat.
  2. Consultant Plastic Surgeon, North West Hospital & Research Centre, Peshawar.
- 

Correspondence: Dr. Alamzeb Khan  
Assistant Professor, Plastic Surgeon Surgical  
Department, SGTH, Swat.  
Email: adenkhan2015@gmail.com, Cell: 0346-9083413

---

Received: November 27th 2018, Accepted: April 10th 2019

Patient's Satisfaction index was evaluated in terms of the natural consistency of the implant, the feel and tolerability of the implant.

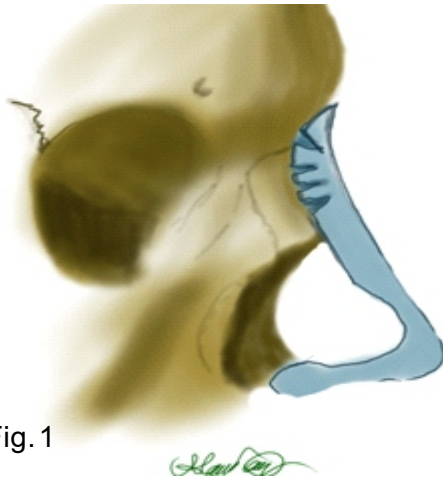


Fig. 1

### RESULTS

A total of 95 patients were included in the study. Out of the total patients 56 were female (58.94%) and 39 were male (41.05%). The age ranged from 17 to 42 years. Mean age was 28.07 years. The total number of patients who had deformity due to previous surgery was 63(66.3%). Patients with post traumatic nasal deformity were 28(29.4%) in number and patients desiring augmentation without previous surgery or trauma were 4(4.2%). Implant extrusion occurred in 2 patients (2.1 %). Re- insertion was performed in one patient and implant was removed and dermal graft inserted in the second patient. Only 1 patient was not satisfied with the appearance of her nose because of the prominence of her lower lateral cartilages post operatively. The patients were followed for a minimum of 6 months post operatively and maximum of 5 years. As a whole the patients were satisfied. There were no reports of unnatural feel of the implant during close contact.

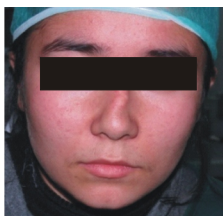


Fig. 2(a)

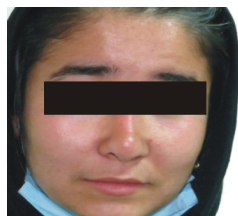

Fig.2 (b)

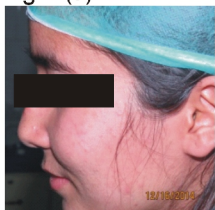

Fig.2(c)

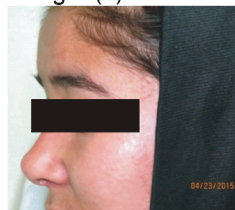

Fig. 2(d)

### DISCUSSION

Rhinoplasty is one the most commonly performed aesthetic surgeries. Augmentation of the nose is a very challenging task because of the idiosyncratic nature of nose. Most of our patients for augmentation had previous surgery by ENT surgeon for functional nasal problems like deviated nasal septum and nasal airway blockage. The second most common cause of nasal deformity was direct trauma to the nose. Very few patients presented with nasal deformity without any cause and the patients desired shape change according to their wishes.

Augmentataion rhinoplasty can be undertaken with autogenous tissue or alloplastic materials. Both methods have their advantages and disadvantages. Alloplastic material is preferred in patients who do not desire the harvest of autologous tissue or those cases in which the desired tissue are not available. The most commonly used materials for augmentation rhinoplasty are Gore-Tex, Medpore and Silicone<sup>6</sup>.

Silicone is our preferred material because its readily available, can be carved according to the need of the patient. We use a readymade implant of various sizes but having L shape. We usually carve the implant during surgery and it does not take more than 10 minutes to prepare the desired contour but some experience is needed. We usually select the smallest possible implant and carve the cephalic part of the implant with a number 15 Bard Parker blade. The caudal part of the implant is split at the terminal part to fix astride on the nasal spine. The carving process also include radiating incisions on the inner surface of the cephalic part. This is to prevent nasion level shift by the implant<sup>7</sup>, as shown in Fig .1.

The incidence of infection and extrusion and displacement in our hands is very low as compared to Deva AK et al who have 5.5% major complications<sup>3</sup>. Although solid silicone is more resistant to infection because of its non porous nature<sup>8</sup>,

Infection in the early postoperative stages can be controlled with strict adherence to aseptic technique, use of antibiotics prophylactically and proper closure of the incisions<sup>9</sup>.

One of the reasons for implant extrusion is tension on the implant<sup>10</sup>.

Displacement is usually due to supra preiosteal placement of the implant. Malposition was attributed to the erroneous technique of dissection by Higara<sup>11</sup>. We make a pocket under the periosteum and rasp the underlying nasal bone a bit to accommodate the implant. The implant is nicely fitted in the pocket and the risk of displacement and extrusion is minimized.

Our patients with augmentation with bone or cartilage grafts complained about the hard and unnatural feel of the nose after surgery. And the problem was mostly felt during close contact. The patients who underwent augmentation with silicone implants were satisfied with their soft natural nose post operatively.

### CONCLUSION

Rhinoplasty is one of the most frequently performed Aesthetic procedures. Nose is augmented with either autologous tissue or synthetic implants. We have a good experience with the silicone implant. Patients with silicone augmentation were satisfied with the cartilage like consistency of the implant. The overall complication rate is less in our cases.

### REFERENCES

1. Rohrich RJ, Ahmad J. Rhinoplasty. *Plastic and reconstructive surgery*. 2011 Aug 1;128(2):49e-73e.
2. Wee JH, Park MH, Oh S, Jin HR. Complications associated with autologous rib cartilage use in rhinoplasty: a meta-analysis. *JAMA facial plastic surgery*. 2015 Jan 1;17(1):49-55.
3. Deva AK, Merten S, Chang L: Silicone in nasal augmentation rhinoplasty: a decade of clinical experience. *Plast Reconstr Surg* 102:/ 1230-1237, 1998.
4. Erlich MA, Parhiscar A. Nasal dorsal augmentation with silicone implants. *Facial plastic surgery: FPS*. 2003 Nov;19(4):325-30.
5. Tham C, Lai YL, Weng CJ, Chen YR. Silicone augmentation rhinoplasty in an Oriental population. *Annals of plastic surgery*. 2005 Jan 1;54(1):1-5.
6. Peled ZM, Warren AG, Johnston P, Yaremchuk MJ. The use of alloplastic materials in rhinoplasty surgery: a meta-analysis. *Plastic and reconstructive surgery*. 2008 Mar 1;121(3):85e-92e.
7. Yang, S. J., and Lee, J. H. Guidelines of successful augmentation rhinoplasty. *J. Korean Soc. Aesth. Surg*. 11: 34, 2005.
8. Smith Jr EM. Silicone: its chemistry and biocompatibility. *The art of alloplastic facial contouring*, Mosby, Philadelphia. 2000:241-50.
9. Zeng Y, Wu W, Yu H, Yang J, Chen G. Silicone implants in augmentation rhinoplasty. *Aesthetic Plast Surg* 2002;26(2):85-88.
10. Lawson W, Reino AJ, Seidman D. The silicone columellar strut. *Plast Reconstr Surg* 1996;97(5):938-943.
11. Hiraga Y. Complications of augmentation rhinoplasty in the Japanese. *Ann Plast Surg* 1980;4(6):495-499.